

Original Article

## SURVEY OF THE HEALTH STATUS OF SOME HONEY BEE QUEENS IN ITALY

Marco Porporato  
Giacomo Grillone  
Augusto Patetta  
Aulo Manino  
Daniela Laurino\*

Univerisity of Turin, Largo Paolo Braccini 2, 10095 Grugliasco, Italy

\*corresponding author: daniela.laurino@unito.it

Received 21 July 2014; accepted 20 November 2015

### Abstract

**While observing: non-acceptance, frequent replacements, and reduced performance in honey bee (*Apis mellifera ligustica*) queens, we were induced to analyse a certain number of queens to detect the causes. For this purpose, 99 newly mated queens were bought from 20 Italian queen breeders. In addition, 109 older or at-the-end-of-their-career queens, that showed poor productivity, were collected from honey production hives throughout Italy. All the queens were dissected to check the status of their reproductive system and/or the presence of various anomalies and diseases.**

**Anatomical and functional anomalies, pertaining to ovaries and spermatheca, also in association with tissue alterations and microorganisms like *Nosema* spp. and protozoa, were common in both newly mated and older queens, but they were more prevalent in the latter. Observed differences permitted us to highlight the causes of the reduced performance of the queens and of the colonies they originated from. The obtained information could prove useful when it comes to improving queen breeding techniques.**

**Keywords:** enterolith, Italy, melanosis, ovaries, protozoa, queens anomalies.

### INTRODUCTION

A honey bee colony, composed of thousands of individuals, can be considered to be like a super organism, with the queen keeping the balance. Colony biological developments and productive results depend on her (Fyg, 1961; Gauthier, 2011; Porporato and Laurino, 2013). Only the queen is able, after mating, to produce the extremely large and essential number of male and female progeny for the prosperity of the colony. She alone possesses fully developed reproductive organs, and can be mated.

Through reproduction, the queen transmits to the progeny her own characteristics as well as those of the drones which mated with her. In this way she determines the good and bad characters of her colony (Fyg, 1961). It is easy to understand that the entire bee colony is adversely affected when the queen is afflicted with hereditary or structural defects, or becomes ill and ceases to lay eggs.

On the contrary, good colony productivity depends on a strong egg-laying queen who is in good condition (Fyg, 1961; Kaftanoglu et al., 1988; Laidlaw, 1992;

Bieńkowska et al., 2011; Büchler et al., 2013). From a general point of view, a "high quality" queen should be heavier, disease-free, have a large sized spermatheca, have a high number of spermatozoa in it, and have a high number of ovarioles. The queens should also have high egg laying ability/fecundity and eventually should have a high brood and population production, show very good hygienic behaviour, should increase honey yield, should show a low degree of defensive behaviour, be calm on the comb, and have a low swarming tendency (Hatjina et al., 2014). All these desired traits have a genetic basis and queens can be selected for them, but it is fundamental to consider the environmental conditions too. The latter influence not only the development of the colony, but also the quality of queens and sperms produced by the drones. Climate, temperature (Fyg, 1961), humidity, pesticides, and other toxic substances (Niño et al., 2011) have a high impact on all the above-mentioned characteristics. Anatomical and physiological anomalies and other issues of a different nature can have an influence on the physical condition of the queen and, consequently

on the development of the colony (Porporato and Laurino, 2013).

The queen's fully developed reproductive system is formed by:

- 2 ovaries, which take up almost all the room in the abdomen. The ovaries are composed overall by 300 - 400 ovarioles, and each of them can give 3 - 5 eggs per day (Jackson et al., 2010; Gauthier, 2011; Porporato and Laurino, 2013). This means that every day, the queen could lay up to 2000 eggs, which in weight, correspond to the average weight of the very queen (Büchler et al., 2013). There is a tendency for the right ovary to contain more ovarioles than the left ovary. A huge physical effort is required to lay eggs, so the queen must be constantly fed with high nutritional food. The queen is fed royal jelly, secreted by the hypopharyngeal glands of the young worker bees, that are members of her court.

- 2 lateral oviducts, each connecting an ovary to the median oviduct or vagina.

- 1 vagina, that continues into a copulating bursa shaped like an oval sac (Snodgrass, 1956; Crane, 1990; Goodman, 2003).

- 1 spermatheca, that preserves live sperm and stores them for several years after mating. It is a small organ with an average diameter of 1.08 mm, totally enveloped by the tracheae, which assure perfect oxygenation, and which is necessary to keep the sperm alive. The spermatheca has a special gland that secretes a fluid with a pH of 8.6 and a proteinic concentration of 15.3 mg/mL. This fluid is fit to assure sperm preservation throughout the life of the queen (Lodesani et al., 2004; Al-Lawati et al., 2009; Gauthier, 2011; Porporato and Laurino, 2013).

The queen mates typically with 15 or more drones and each of the drones can supply as many as 10 million sperm; only some of these sperm, crossing the vagina and the copulating bursa, reach the spermatheca and are stored there (Goodman, 2003; Porporato and Laurino, 2013). The sperms spill from the spermatheca only when they must fertilise the eggs that descend from the ovaries.

A fertilised queen, during oviposition, has an average weight of 180 mg. Small queens can be excellent egg-layers as can larger queens.

Oviposition rhythm is regulated by several internal and external factors: genetic characters, availability of space, diseases and/or anomalies, weather conditions, availability of food resources, and toxic substances from agricultural activities or pollution (Porporato and Laurino, 2013). Polluting molecules can in fact induce negative consequences on queen

and drone quality. Similar effects were demonstrated not only for animals but also for humans (Matsuda et al., 2009).

Although it is not difficult for the beekeepers to replace an unfit queen before the colony is weakened, research into diseases and anomalies of queens is necessary for scientific reasons, and important from a practical standpoint as well. Knowing about the many anomalies and diseases allows for deciding whether it is the queens fault for a weak or manifestly diseased bee colony (Fyg, 1961).

The aim of the research was to provide a brief review on the numerous and most important heterogeneous anomalies and diseases that can be found in queen bees in Italy.

## MATERIAL AND METHODS

The study was an analysis that was conducted in 2012 and 2013. Ninety-nine newly mated queens of the subspecies *A. m. ligustica* were bought between 20 July - 2 August, 2012 from 20 queen breeders of different regions in Italy. One hundred and nine older queens, that were removed from their colonies by eight beekeepers (1 - 55 queens/beekeeper) because the queens were not effective or were at the end of their career, were also used in the study. The queens were observed exteriorly and dissected immediately after killing to preserve the ovaries that otherwise become extremely brittle (Dade, 1962). Dissections were carried out using the method suggested by Dade (1962).

The queens were divided according to age and were weighed with an analytical scale. For each queen, the following data were registered: number of ovarioles in the right ovary, diameter of the spermatheca, number of sperm in the spermatheca, the presence of *Nosema* spp. spores in the queen, and for the queens that had accompanying workers in their cages, also for these worker bees.

### *Number of ovarioles*

Only the ovarioles in the right ovary were counted. The number of ovarioles was estimated with a method derived from Jackson et al. (2010). The ovary was dissected in a saline solution and removed. It was kept in Coomassie brilliant blue for 10 seconds, and then cut into two parts with a transverse section. The upper part of the ovary was placed under a Nikon SMZ-U stereomicroscope (Nikon Corporation, Tokyo, Japan), the ovarioles were separated with the dissecting needle and counted.

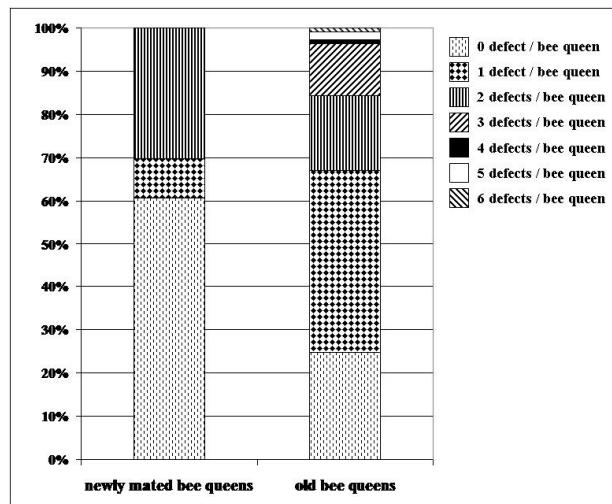


Fig. 1. Number of defects / queen in newly mated and old queens.

*Diameter of the spermatheca*

The diameter of the spermatheca was evaluated after removal of the tracheal net which surrounds it. Since spermathecae do not have a perfect spherical form, three orthogonal diameters were measured and their average was calculated.

Very accurate results were obtained by use of digital photographs and an Image Analysis system using Leica Microsystems MZ 16 A (Leica Ltd, Heerbrugg, Switzerland).

*Number of sperm*

The tracheal net that surrounds the spermatheca was removed. The spermathecal content was dispersed in a volume of saline solution (1 mL of NaCl 0.15%) and then homogenated. A drop of this suspension was used for counting the sperms in a standard hemacytometer counter chamber (Burker Camera) under a light microscope (Human et al., 2013).

*Nosema spp. spores*

The digestive system of the queen was analysed after being removed from the abdomen. The digestive system was macerated in a 1 ml saline physiologic solution of 0.9%. A drop of this suspension, was used for counting the spores in a standard hemacytometer counter chamber (Burker Camera) under a light microscope (Human et al., 2013). If there were also worker bees with the queens, nosema analysis was done on them using the same method.

*Statistical analysis*

Differences observed in the quantitative features of newly mated and old bee queens were compared

with the Mann-Whitney Rank Sum Test using the PAST (Hammer et al., 2001) statistical package.

**RESULTS**

Observed queen defects are summarised in Tab. 1. The sum of the defects is greater than the number of defective queens because many queens showed more than one anomaly. Up to 6 defects per queen were observed in old queens, who altogether showed many more anomalies than newly mated queens. Most of the newly mated queens had no defects and only 20.5% of the defective, newly mated queens showed 2 defects (Fig. 1).

Body weight and some reproductive system features observed in newly mated and old queens are shown in Tab. 2. Newly mated queens were significantly lighter and had significantly less ovarioles and sperm in their spermathecae than older ones. The overall average number of sperm found in each spermatheca was 5,093,006.

During a first visual observation, some queens had abnormal colourations, reduced dimensions, or other immediately visible characteristics and anomalies. All the subjects with these characteristics always showed anatomic/functional anomalies. Among structural abnormalities, malformations of the abdomen and wings were noteworthy (Tab. 1; Fig. 2a,b,c). It was also observed that often "sister queens" had common characteristics, such as weight, number of ovarioles, and various anomalies.

*Ovarian anomalies and diseases*

The ovaries were quite rudimentary, but all other parts of the reproductive organs were well

Table 1.

Number of defects present in newly mated and old bee queens

	Newly mated bee queens	Old bee queens
number of queens*	99	109
defects*	39	82
no defects	60	27
<b>OVARY</b>		
absence of one ovary	0	1
hypoplasia/atrophy of ovaries	1	18
other ovarian problems	0	1
melanosis	0	42
viroses	0	2
absence of oviducts	0	1
other egg anomalies	1	2
<b>SPERMATHECA</b>		
absence of spermatheca	0	2
abnormal shape of spermatheca	9	14
double spermatheca	1	1
white spermatheca	1	3
transparent spermatheca	0	2
black spermatheca	0	2
8 shaped spermatheca	4	6
absence of sperms	2	6
abnormal sperms	0	2
<b>OTHER PATHOLOGIES</b>		
deformed wings	2	3
deformed abdomen	1	3
<i>Nosema</i> spp. spores	3	2
flagellate protozoa	10	2
ciliate protozoa	12	0
enteroliths	0	5
abnormal malpighian tubules	0	1
abnormal proventricolus	0	1

\*the sum of the defects is greater than the number of defected bee queens.

Table 2.

Quantitative features of newly mated and old bee queens

	Newly mated queens		Old queens		P*
	mean	SD	mean	SD	
body weight (g)	0.186	0.024	0.210	0.042	<0.001
number of ovarioles	74.45	14.56	81.63	25.03	0.001
diameter of spermatheca (mm)	1.133	0.204	1.126	0.162	0.068
volume of spermatheca (mm <sup>3</sup> )	0.811	0.383	0.779	0.380	0.080
number of sperms	2,993,517	3,714,567	7,170,395	10,721,670	<0.001

\*Probability of Mann-Whitney Rank Sum Test




Fig. 2. **a** Queen with a malformation of the abdomen. **b** Queen with wing deformations. **c** Queen with a malformation of abdomen and wings. **d** Normal apparatus of the queen. **e** Queen with rudimentary ovaries. **f** Queen without one ovary. **g** Queen without oviducts. **h, i** Queens with melanosis of the ovaries.




Fig. 3. **a** Queen with melanosis of the ovaries. **b** Queen with ovarian atrophy. **c** Queen with the presence of dead tissues in the proximal part of ovaries and melanosis in the distal part.

developed (Fig. 2e). The few ovarioles in the rudimentary ovaries contained only degenerated germ cells.

There was only one case where there was an absence of one ovary. The queen had only the left ovary (Fig. 2f) and there were no eggs in the ovarioles.

There was an absence or malformation of the oviducts in some queens. Usually only one of the oviducts was malformed, but sometimes both were malformed (Fig. 2g).

Melanosis, a very important pathology of the queen's ovaries, was observed in 42 of the 109 older queens, but in not one of the newly mated queens. Melanosis is characterised by discolouration of the egg cells

and trophocytes which turn from yellow-brown to black (Fig. 2h,i; Fig. 3a).

Ovarian atrophy (Fig. 3b) was also frequent in queens. It was observed in young as well as in older queens. Ovarian atrophy was characterised by a rapid disintegration of the contents of the ovarioles, with relative withering and volume reduction.

A yellow colouration was frequently found in the terminal parts of the ovaries and corresponded with the presence of dead tissues (Fig. 3c).

*Spermatheca anomalies and diseases*

Usually every queen had only one spermatheca, but in some cases there were two spermathecae. Such a phenomenon appeared twice out of 208 queens.



In these cases, the two spermathecae were always in a single tracheal wrapping. It was possible to observe the spermathecae only after the removal of the tracheae (Fig. 4a); the average number of sperm was 2,005,208.

Other interesting anomalies of the spermatheca were: the absence of the spermatheca, the small size of the spermatheca compared to average dimensions, and an abnormal spermatheca shape (Fig. 4b). Frequently, spermathecae with an irregular shape, like the number "8" (Fig. 4d), were found. The average number of sperm inside these irregularly shaped spermathecae was 9,560,417.

The spermatheca is characterised as having an external pearl colour, but we found different kinds of colours with relative differences. In all of our findings, white spermathecae never had sperm inside (Fig. 4e). Queens with white spermathecae were always replaced; they were not accepted, and they failed to lay eggs. Transparent spermathecae were found in an important number of queens (Fig. 4f). The transparent spermathecae were without sperm. In one case, a black spermatheca was found (Fig. 4g). This queen was characterised by nonacceptance and she failed to lay eggs, yet she presented a high number of vital sperm inside the spermatheca.

*Other anomalies and diseases*

Two new and two old queens showed rather high levels (more than one million spores/queen) of *Nosema* spp. spores. Also their accompanying worker bees were infected. Similar levels of *Nosema* spp. spores were also found in the accompanying workers of several queens in which the queens were not infested (Fig. 5a).

Of special interest were the pathological stone formations or enteroliths in the rectum of the queens. These enteroliths were reminiscent, in many cases, of gall-stones, renal and urinary calculi of human and domestic animals (Fig. 5b, c). The enteroliths appeared in the rectum as single or several hard, spherical or polymorphous concretions, which often formed agglomerations. Four of the examined queens had enteroliths. The average diameter of the enteroliths was 409.6 µm. The colour was quite variable: from brick red to grey-brown or brownish-black.

The majority of enteroliths showed a distinct concentric stratification and an outward radiating structure.

In one queen, very dark Malpighian tubes were found (Fig. 5d). Similarly, only one queen presented an abnormal proventriculus which was stiff and very dark in colour (Fig. 5e).

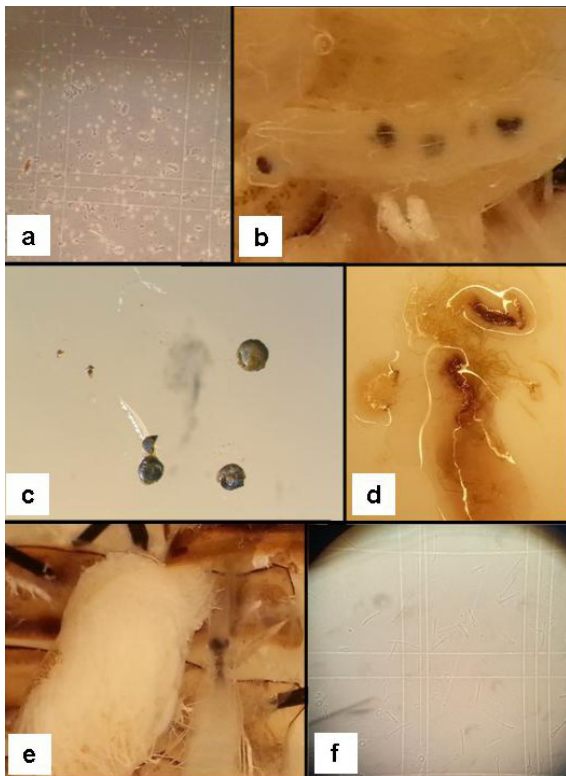


Fig. 4. **a** Queen with two spermathecae. **b, c** Spermathecae with non-conformable shapes. **d** Spermatheca with an "8" shape. **e** White spermatheca. **f** Transparent spermatheca. **g** Black spermatheca.

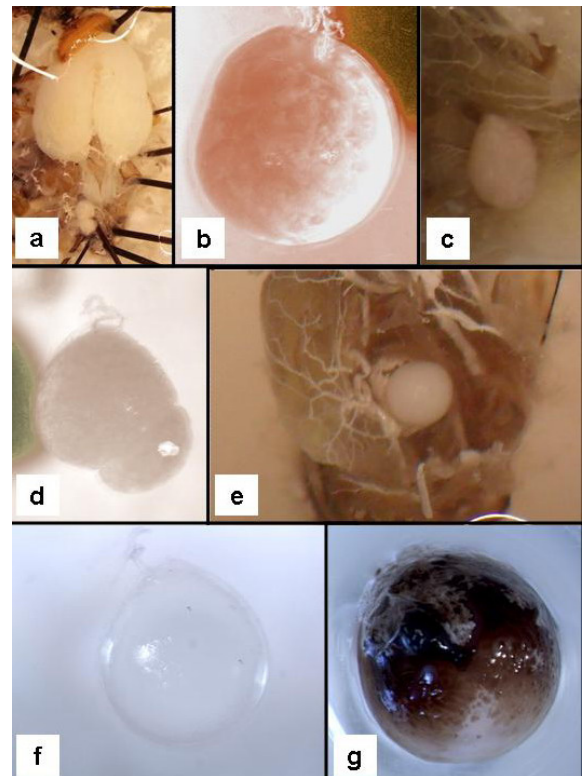


Fig. 5. **a** *Nosema* spp. spores in the a queen. **b** Enteroliths in the rectum of a queen. **c** Details of enteroliths. **d** Anomaly of Malpighian tubes. **e** Anomaly of a proventriculus. **f** Sperm anomalies.

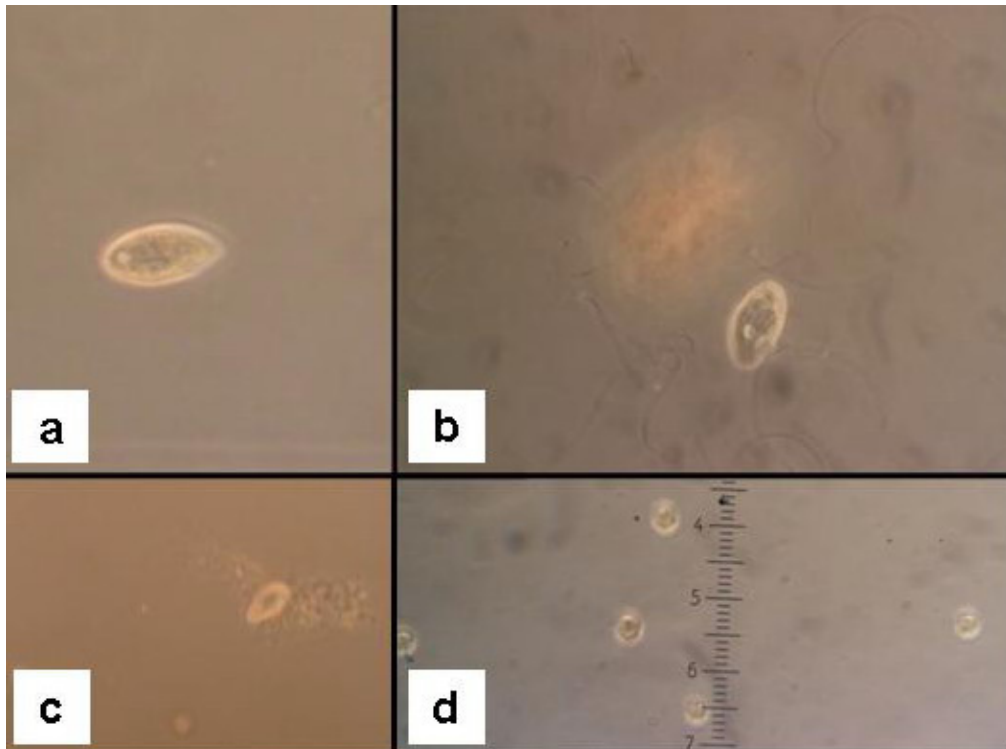


Fig. 6. **a** Ciliate protozoa of the genus *Tetrahymena* in the spermatheca. **b** Ciliate protozoa of the genus *Tetrahymena* surrounded by sperm in the spermatheca. **c** Ciliate protozoa of the genus *Tetrahymena* and flagellate protozoa surrounded by sperm in the spermatheca. **d** Flagellate protozoa in the spermatheca.

Sometimes, while observing the spermatheca, it was possible to find the presence of degenerated sperm, which were curled into ringlets. Each ringlet consisted of only one sperm. In some cases, other sperm anomalies were found. For example, sperm that appeared rolled up, forming a "loop knot" on one extremity (Fig. 5f).

In 22 queens, protozoa were observed in the spermatheca. Two different kinds of protozoa were identified: ciliate and flagellate protozoa (Fig. 6a,b,c,d). The ciliate protozoa are representatives of the order Hymenostomatida, genus *Tetrahymena*, probably *T. rostrata*. The flagellate protozoa could not be identified.

## DISCUSSION

Newly mated queens are smaller than older ones since queens can reach their reproductive potential only after they are put into fully developed hives (Laidlaw, 1992). For this reason, weight differences observed in the present study were not surprising. On the contrary, ovariole number does not change during a queen's adult life. Ovariole numbers from this study were lower than those reported in the literature (Jackson et al., 2010; Gauthier, 2011) especially when young queens were considered. Low ovariole numbers can be the result of defective

genetic characteristics and/or of poor rearing conditions and can lead to rapid queen supersedeure. In any case, further investigations are needed to highlight the extent of this phenomenon and to understand its causes.

Substantial discrepancies in the average number of sperm found in each spermatheca are reported in the literature: 1 - 8 million in queens just mated, with an average of 3.5 million during the life of the queen (Al-Lawati et al., 2009); 4.7 - 5.3 million (Gerula et al., 2012); over 7 million (Bieńkowska et al., 2011). The average sperm number observed by us in newly mated queens, indicates that inadequate mating and/or that defective sperm transfer into the spermatheca occurred at least in a substantial part of the sampled queens as the figures of the first and the second quartiles suggest: 1,184,896 and 1,994,792 sperms, respectively. To better understand the phenomenon, data on drone populations in the mating yards and on attendant workers in the mating nuclei are needed. Nonetheless, the effect of adverse weather conditions should also be considered since all newly mated queens were bought in the same short period at the end of July 2012 and they had probably mated more or less during the same days. On the contrary most of the examined old queens should have received a normal number of sperm when they mated. The lower

sperm counts found in some of the older queens can be easily explained by the queen's age. In fact, sperm number and activity decrease considerably as the queens get older. Sperm number and activity are influenced by temperature conditions. After the first year of a queen's life, only 38% of sperm are still present in the spermatheca, and after the second year, only 21% of the sperm are still present in the spermatheca compared with the normal sperm number of a just mated queen (Al-Lawati et al., 2009).

Indirectly, also the quality of the drones and the quality of their sperm influences not only the colony but also the activities of the queens after mating. For example, it was demonstrated that, in drones, the insecticide coumaphos has negative effects on sperm vitality (Burley et al., 2008; Gauthier, 2011).

#### *Ovarian anomalies and diseases*

Ovarian atrophy, the development failure or hypoplasia of the ovaries, causes permanent sterility (Fyg, 1961). The cause of this disease is not yet known, but a viral agent may be involved.

Absence or malformation of the oviducts probably originate during postembryonic development. According to Löschel (1916), the genital ducts of the queen are formed from paired imaginal discs on the ventral side of the tenth segment, and initially they are not connected with the ovaries. Only during the prepupa and pupa stages do the lateral oviducts extend into the body cavity towards the gonads as hollow ectodermal invaginations and connect with the ovaries, generally on the third day of the pupal period.

Occasionally, the oviducts may stop growing before they have reached the ovaries. When this happens there will be no connection between the normally developed ovaries, which are closed at the posterior ends, and the vagina (Fyg, 1961). Queens with a single malformed oviduct are able to lay eggs to a limited extent. Defects of the oviducts do not exclude a successful mating (Fyg, 1961).

We observed melanosis in old queens only as it was to be expected, since melanosis is usually a reaction to various degenerative effects which can be due to different causes. In the case of ovary stoppage, the accumulated proteins would decompose and be transformed into melanin by oxydizing enzymes (Arnhart, 1929), sperm masses can block the oviducts after fungal infections in the genital passages or a viral infection may be involved. Very often, though, these degenerative effects derive from long term intoxication. Experimental studies showed that the coumaphos molecule, used for varroa control, had

a negative effect on young queen development (Burley et al., 2008; Gauthier, 2011).

#### *Spermatheca anomalies and diseases*

Peterka (1938), Gontarski (1951), and Fyg (1961) described, as a very rare exception, a queen with two spermathecae. In our research, this phenomenon was more frequent. In the cases examined by the authors, the two spermathecae, with many sperm, were close together and led separately into the vagina. Löschel (1916) explained that the spermatheca is formed in the prepupal stage from two separatedanlagen, and it can be assumed that they did not unite during this stage, but continued to develop independently. The "8" shaped spermathecae could be explained by this theory; also the higher number of sperm counted in these unusual spermathecae, compared to the average number inside of the normal ones, suggests a double origin for "8" shaped spermathecae.

#### *Other anomalies and diseases*

The *Nosema* disease, to which the queen is as susceptible as the worker (Fyg, 1961), is often the cause of the loss of queens in colonies or nuclei. Therefore, the observed number of queens with high *Nosema* spp. spore counts can be considered rather low. *Nosema* spp. spores had been reported from the ventricular epithelium and the midgut, but also the fat body and the ovaries (Steche, 1960; Fyg, 1961; Gauthier, 2011). Although the queen is very susceptible to the disease, she may frequently remain immune to the infection in a diseased colony (Fyg, 1961), but the queens of colonies highly affected by the disease resulted in infection with spores too (Vecchi, 1972). In most cases, young queens are not capable of surviving a high level of *Nosema* (Alaux et al., 2011; Traver and Fell, 2012).

The enterolith structure was first described by Fyg (1961), who also observed an accumulation of faeces and a considerable enlargement of the hind gut and stated that enterolithes are formed primarily on the rectal epithelium which the enteroliths are connected to by a short stalk. Chemical examinations proved that enteroliths consist mainly of uric acid (Fyg, 1961). Larger stones exert a pressure on the genital ducts lying under the rectum and prevent ovoposition as a consequence (Fyg, 1961). Usually the queens become sterile, though the infection does not spread to the reproductive organs. Enteroliths and bacillary infections may cause an accumulation of faeces in the rectum, affecting all abdominal organs (Fyg, 1961).

Dark Malpighian tubes surely play a part in the



patology of the queens, but no record of them was found in the literature.

Arnhart (1929) described a peculiar anomaly of the sperm, which he described as "Ringelsamen". His opinion was that the degeneration of sperm is to be attributed to damage from chilling which may occur in springtime and late autumn when a sudden drop in the temperature takes place. But this causal explanation does not seem to be correct because the morbid drone-laying not only appears in springtime and autumn but often during the summer months as well (Fyg, 1961). Also sperm forming a "loop knot" on one extremity showed a shape totally different from the normal shape (Dade, 1962; Al-Lawati et al., 2009).

Ciliate and flagellate protozoa are a common occurrence in the gut of worker bees and are sometime reported as pathogenic organisms, but they had never been observed till now in spermathecal fluid (Fries, 1997).

Other cases of anomalies and diseases of queens are cited in the literature, but they were not observed in this study. The cited ones include: accessory ovarioles, ovary and spermatheca tumours; septicaemia due to bacterial infection in the haemolymph or in the ovaries (Fyg, 1961); infections of *Malpighameba mellificae* and *Acarapis woodi*, since the queen is susceptible to acarine disease (Morgenthaler, 1933).

## CONCLUSIONS

The presence of diseases, anomalies, and defects in most of the old queens that are removed from their colonies by beekeepers because of their defects or because they are at the end of their career, is not surprising. The fact that the beekeeper only acts when more than a single defect is present is noteworthy. On the other hand, queen breeders are expected to produce and distribute top quality newly mated queens, whose reproductive performance should have been tested in the mating nuclei before shipment to customers. The prevalence of diseases, anomalies, and defects that emerged during the present investigation in a large part of the examined young queens, could easily explain the fact observed by several Italian beekeepers, that often newly mated queens are not accepted or rapidly replaced by fully developed colonies. However, it poses some serious questions not only about the genetic characteristics of the reared honey bee strains, but also about the rearing methods adopted by a not negligible part of Italian queen breeders and on mating station environmental conditions. In

any case, defective queens could play a significant role in honey bee colony decline, and queen features should be taken into account when analysing the phenomenon.

## ACKNOWLEDGMENTS

We thank Prof. Franco Verni of the University of Pisa for the assistance with the protozoa, and the many beekeepers who provided the queens.

## REFERENCES

- Al-Lawati H., Kamp G., Bienefeld K. (2009) Characteristic of the spermathecal contents of old and young honeybee queens. *Journal of Insect Physiology* 55: 117-122. DOI: 10.1016/j.jinsphys.2008.10.010
- Alaux C., Folschweiller M., McDonnell C., Beslay D., Cousin M., Dussaubat C., Brunet J.-L., Conte Y. L. (2011) Pathological effects of the microsporidium *Nosema ceranae* on honey queen physiology (*Apis mellifera*). *Journal of Invertebrate Pathology* 106: 380-385.
- Arnhart L. (1929) Beiträge zur Kenntnis von Krankheiten der Bienenkönigin, die zur Störung der Eiablage führen. *Archiv für Bienenkunde* 10: 107-139.
- Bieńkowska M., Panasiuk B., Węgrzynowicz P., Gerula D. (2011) The effect of different thermal conditions on drone semen quality and number of spermatozoa entering the spermatheca of queen bee. *Journal of Apicultural Science* 55(2): 161-168.
- Burley L., Fell R. D., Saacke R. G. (2008) Survival of Honey Bee (Hymenoptera: Apidae) Spermatozoa Incubated at Room Temperature from Drones Exposed to Miticides. *Journal of Economic Entomology* 101: 4. DOI: 10.1603/EC11276
- Büchler R., Andonov S., Bienefeld K., Costa C., Hatjina F., Kezic N., Kryger P., Spivak M., Uzunov A., Wilde J. (2013) Standard methods for rearing and selection of *Apis mellifera* queens. *Journal of Apicultural Research* 52(1): 1-29.
- Crane E. (1990) *Bees and Beekeeping - Science, Practice and World Resources*. Heinemann Newnes. Oxford. 614 pp.
- Dade H. A. (1962) *Anatomy and dissection of the honeybee*. Bee Research Association. London. 158 pp.

- Fries I. (1997) Protozoa. In: Morse R. A., Flottum K. (Eds.) Honey bee pests, predators, and diseases. The A. I. Root Company. Medina, Ohio: 57-76.
- Fyg W. (1961) Anomalies and diseases of the queen honey bee. *Annual Review of Entomology* 9: 207-224.
- Gauthier L. (2011) La qualité des reines (et des mâles). *Revue Suisse d'Apiculture* 4: 16-24.
- Gerula D., Panasiuk B., Węgrzynowicz P., Bieńkowska M. (2012) Instrumental insemination of honeybee queens during flight activity predisposition period 2. Number of spermatozoa in spermatheca. *Journal of Apicultural Science* 56: 159-167.
- Gontarski H. (1951) Duplizität der Samenblase einer Königin von *Apis mellifica*. *Zeitschrift für Bienenforschung* 1: 41.
- Goodman L. (2003) Form and Function in the Honey Bee. IBRA. Cardiff. 220 pp.
- Hammer Ø., Harper D. A. T., Ryan P. D. (2001) PAST: Paleontological Statistics Software Package for Education and Data Analysis. *Palaeontologia Electronica* 4(1): 9.
- Hatjina F., Bieńkowska M., Charistos L., Chlebo R., Costa C., Dražić M. M., Filipi J., Gregorc A., Ivanova E. N., Kezic N., Kopernicky J., Kryger P., Lodesani M., Lokar V., Mladenovic M., Panasiuk B., Petrov P. P., Rašić S., Smodis Skerl M. I., Vejsnæs F., Wilde J. (2014) A review of methods used in some European countries for assessing the quality of honey queens through their physical characters and the performance of their colonies. *Journal of Apicultural Research* 53(3): 337-363. DOI: 10.3896/IBRA.1.53.3.02
- Human H., Brodschneider R., Dietemann V., Dively G., Ellis J. D., Forsgren E., Fries I., Hatjina F., Hu F. -L., Rodolfo R., Bruun Jensen A., Köhler A., Magyar J. P., Özkýrým A., Pirk C. W. W., Rose R., Strauss U., Tanner G., Tarpý D. R., van der Steen J. J. M., Vaudo A., Vejsnæs F., Wilde J., Williams G. R., Zheng H. -Q. (2013) Miscellaneous standard methods for *Apis mellifera* research. *Journal of Apicultural Research* 52(4): DOI: 10.3896/IBRA.1.52.4.10
- Jackson J. T., Tarpý D. R., Fahrbach S. E. (2010) Histological estimates of ovariole number in honey queens, *Apis mellifera*, reveal lack of correlation with other queen quality measures. *Journal of Insect Science* 11: 82.
- Kaftanoglu O., Duzenli A., Kumova U. (1988) A study on determination the effects of queen rearing season on queen quality under Cukurova region conditions. *Turkish Journal of Veterinary and Animal Science* 16: 567-577.
- Laidlaw H. H. Jr. (1992) Contemporary queen rearing. Dadant & Sons Inc. Hamilton, IL. 199 pp.
- Lodesani M., Balduzzi D., Galli A. (2004) A study on spermatozoa viability over time in honey bee (*Apis mellifera ligustica*) queen spermathecae. *Journal of Apicultural Research* 43: 27-28.
- Löschel F. (1916) Die postembryonale Entwicklung des Geschlechtsapparates der Bienenkönigin. *Zeitschrift für Angewandte Geologie* 3: 21-44.
- Matsuda K., Kanaoka S., Akamatsu M., Sattelle D. B. (2009) Diverse actions and target-site selectivity of neonicotinoids: Structural insights (Short Survey). *Molecular Pharmacology* 76: 1-10.
- Morgenthaler O. (1933) *Acarapis woodi* in queens. *Bee World* 14: 81.
- Niño E. L., Tarpý D. R., Grozinger C. (2011) Genome-wide analysis of brain transcriptional changes in honey bee (*Apis mellifera* L.) queens expose to carbon dioxide and physical manipulation. *Insect Molecular Biology* 20: 387-398.
- Peterka V. (1938) Zrůdny semmený váček včeli matky. *Včela Moravska* 72: 511-515.
- Porporato M., Laurino D. (2013) Api Regine: anomalie e problematiche. *L'Apis* 4: 23-25.
- Snodgrass R. E. (1956) Anatomy of the honey bee. Comstock Publishing Associates. Ithaca. 334 pp.
- Steche W. (1960) Ätiologie und Therapie der Nosematose der Honigbiene. *Zeitschrift für Bienenforschung* 5: 49-92.
- Traver E. B., Fell R. D. (2012) Low natural levels of *Nosema ceranae* in *Apis mellifera* queens. *Journal of Invertebrate Pathology* 110: 408-410.
- Vecchi M. A. (1972) Osservazioni su eventuali cause determinanti un anormale comportamento della regina. In: Simposio internazionale di apicoltura "Problemi di flora mellifera e impollinazione", Apimondia. Torino-Italy. 2-6 October 1972: 146-152.