

MINIMALLY INVASIVE RADIOFREQUENCY ABLATION FOR LARGE THYROID TOXIC ADENOMA

M. Belitova¹, S. Ivanov², Ts. Marinov¹, T. Popov³, R. Pandev²

¹Department of Anesthesiology & Intensive Care, Medical University – Sofia, Bulgaria

²Department of General Surgery, Medical University – Sofia, Bulgaria

³Department of ENT, Medical University – Sofia, Bulgaria

Abstract. Background: Most thyroid nodules are benign and do not need intervention. Toxic adenoma and toxic multinodular goiter (MNG) are common causes of hyperthyroidism, second in prevalence only to Graves' disease. Toxic adenoma and MNG are the result of focal or diffuse hyperplasia of thyroid follicular cells whose functional capacity is independent from regulation by the thyroid stimulating hormone (TSH). When conservative treatment modalities fail to ensure an euthyroid state, surgical intervention is required, typically surgical left or right thyroid lobectomy. Radiofrequency ablation (RFA) is a new percutaneous treatment option that results in thermal tissue necrosis and fibrosis. As a result of this process, the thyroid nodules shrink. **Case presentation:** We describe a case of a young woman with a large toxic thyroid adenoma who refused surgery. She was admitted to a one-day surgery unit and underwent radiofrequency ablation under total intravenous anesthesia. Using "moving shot technique" the procedure went uneventfully and the toxic adenoma displayed a significant volume reduction with resolution of the hyperthyroid symptoms. The patient also reported a significant improvement of her neck symptoms (from 7/10 to 1/10 on a Visual Analogue Scale). **Conclusions:** Radiofrequency ablation is a new, well tolerated, safe and effective treatment option in selected patients with benign thyroid nodules, toxic adenomas of the thyroid gland and multinodular goiter. To the best of our knowledge, this is the first time such treatment modality is used in Bulgaria.

Key words: radiofrequency ablation, minimally invasive, thyroid adenoma

Corresponding author: Assoc. Prof. Maya Belitova, MD, PhD, Department of Anesthesiology and Intensive Care, Medical University, 1 "Sv. Georgi Sofiyiski" Blvd., 1431 Sofia, Bulgaria, tel.: +359 898 55 14 65, e-mail: belitova@mail.bg

INTRODUCTION

Most thyroid nodules are benign and do not need intervention [1]. However, some thyroid nodules are associated with progressive growth and may result in compressive symptoms and cosmetic concerns that might require intervention – typically thyroid surgery. Radiofrequency ablation (RFA) is a percutaneous treatment that results

in thermal tissue necrosis and fibrosis [1, 2]. Clinical trials demonstrated between 30 and 80% reduction in thyroid nodule volume, durable shrinkage and improvement of neck compression symptoms in patients after thyroid RFA [2-5].

CASE PRESENTATION

A 38-years-old woman discovered the presence of a mass on neck palpation. Her family history indicated

an absence of thyroid illnesses, and she disclosed no past medical history. The patient was an office worker who did not live in an iodine-poor area, and reported having a good dietary intake of iodine. She neither smoked, nor drunk alcohol and was not taking any medication. Her vital parameters: body mass index (BMI), blood pressure, heart rate and temperature were normal (BMI 21,4 kg/m²; BP 100/65 mm Hg; HR 74 beats/min and t 36,4°C, respectively). A physical examination confirmed the presence of a soft-elastic mass in the right portion of her neck which was mobile on swallowing. The patient underwent an ultrasound (US) scan, which showed a large, single, structurally heterogenic and anisoechoic nodule with dimensions: anteroposterior × laterolateral × craniocaudal diameters 35 × 40 × 45 mm, respectively, located in the right lobe of the thyroid gland and exhibiting increased blood flow. The patient also experienced some neck discomfort. Her score was 7-8/10 on a Visual analog scale. Laboratory tests revealed a hyperthyroid state (TSH concentration of 0, 01 mIU/L). The 99mTc SPECT CT scan (Figure 1) revealed a toxic adenoma in the right thyroid lobe. The patient was given thyrostatic medication and later underwent a fine-needle aspiration biopsy (FNAB) with evacuation of about 10 ml dark colloid content, the cytological evaluation of which revealed Bethesda II – a benign nodule [3].

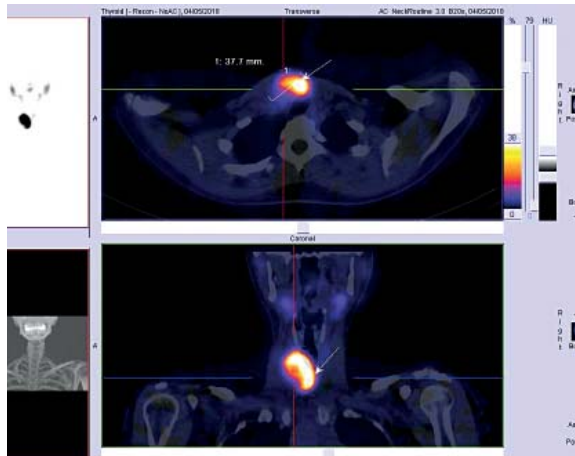


Fig. 1. m99 Tc SPECT CT scan showing a toxic adenoma in the right lobe of the thyroid gland

Because the patient refused surgery, we proposed sclerotherapy but the effect was unsatisfactory in relation to thyroid function – TSH level 0, 11 mIU/L. The results of her other cardiac, pulmonary, abdominal and neurological examinations were unremarkable.

Once again for fear of surgery, the patient refused surgical right thyroid lobectomy, and we proposed RFA of the nodule. After a second FNAB (Bethesda II – a benign nodule), a phoniatric evaluation which excluded abnormalities in the vocal cord motion, an electrocardiogram (no arrhythmias) and after anesthesiologist's report (no other physical pathology), the patient underwent a single session RFA of the autonomously functioning nodule, located in the right thyroid lobe. The manipulation was carried out in a one-day surgery hospital setting. Due to the large volume of the nodule, RFA was performed by means of transisthmic access through 5 entry points, using 7-cm 18-gauge electrode-needle with a 1-cm active needle tip. Also, because of the large volume of the toxic adenoma and the need for motionless patient, analgesia and postoperative pain prophylaxis, opiate-based deep sedation technique without muscle relaxation but with cumulative doses of Propofol 8,3 mg/kg and Fentanyl 8mcg/kg was used. Ventilation during procedure, lasting 35 min was uneventfully achieved by face mask.

Under continuous US scan (Sonosite Edge II, linear transducer 6 cm, 13-6MHz) for verification of internally cooled electrode-needle tip proper location, minimally invasive percutaneous RFA (RFA generator CoAtherm AK, Korea) was done by moving-shot technique (Figure 2) with a delivered energy 41,868 J (3489 J/ml).

The procedure was well tolerated by the patient and no adverse events were noted. After completion of the procedure, the patient was awaked and transferred to a post-anesthesia unit. The sides of fine needle entry-points were visible on the skin of the patient's neck until 5-th post-procedural day. The patient experienced no complains and was discharged from the hospital on the next day (well below 23-hours in-hospital stay) in a self-reporting perfect condition with prescription of TSH control after 2 months. Over the next thirty days, the patient reported a progressive improvement

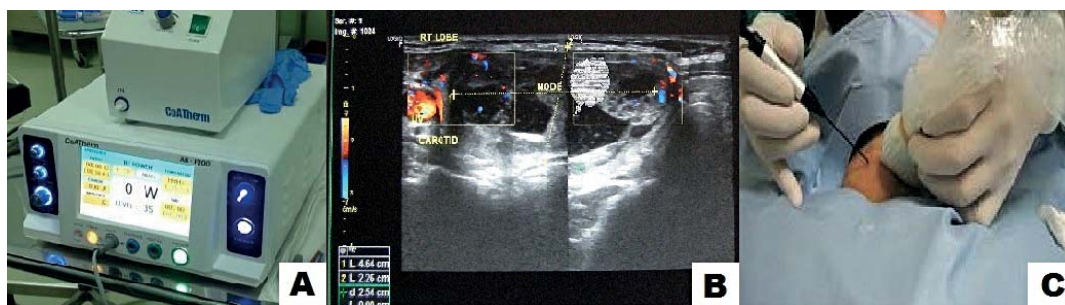

Fig. 2. RFA generator CoAtherm AK, Korea (A); US scan guiding during RFA (B); Start of RFA (C)

of her neck symptoms and cosmetic complains. She was followed-up by US scan until the first month, when marked, visible and progressive (Figure 3) reduction of nodule size was achieved. The patient's thyroid function was still slightly hyperthyroid but with a tendency to normalization – TSH 0, 19 mIU/L.

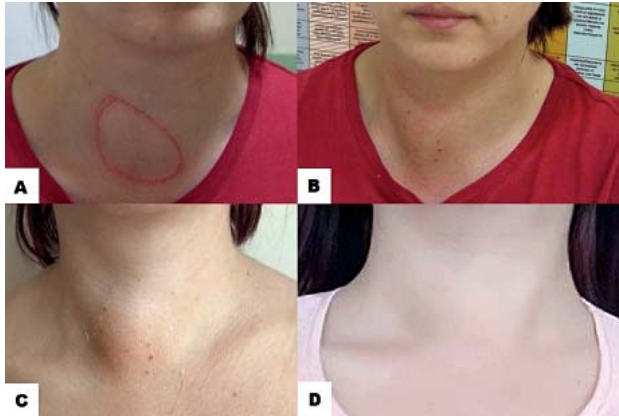

Fig. 3. The patient before RFA (A); 2 hours after RFA (B); 2-nd day after RFA (C); 27 days after RFA (D)

DISCUSSION

To the best of our knowledge, this is the first description in Bulgaria of the effect of minimally invasive percutaneous ablative technique performed in a patient with a toxic adenoma of the thyroid gland, as an alternative treatment option to surgery. We report a case of a young woman who underwent RFA for the treatment of large toxic adenoma in the right thyroid lobe, after refusing right thyroidectomy. RFA has been offered to patients with large (≥ 3 cm), predominantly solid thyroid nodules [4-6, 9] that demonstrated growth or were causing compressive symptoms and cosmetic concerns. The therapeutic success cut-off edge for minimally-invasive radiofrequency ablative techniques is defined as nodule volume reduction $> 50\%$ [4-6, 11]. Some factors that might predict a RFA therapeutic success, though these are controversial are: small volume (< 10 ml) of the nodule at baseline [9], the absence of vascularization [10], nonfunctioning status [2], the presence of fluid and well-defined margins [2, 7-9]. In our patient, the thyroid nodule volume was large (> 13 ml), the adenoma was autonomously functioning (toxic adenoma) with marked vascularization but had well-defined margins and contained colloid fluid component inside; thus, making the value of these predictive factors questionable. Additional studies should be conducted in similar patient populations with a particular focus on factors predicting greater response to RFA and comparing the performance of RFA with other procedures.

CONCLUSION

Ultrasound-guided radiofrequency ablation for thyroid lesions is a well-tolerated, minimally invasive treatment modality with a good efficacy and safety profile that might be an alternative to conventional surgery in patients with thyroid nodules. It is a useful tool for the management of related cosmetic complains and pressure symptoms as well as a valuable option for the treatment of hyperactive thyroid toxic nodules in patients refusing surgery.

Conflict of interest

Authors report no conflict of interest in the publication of the article.

Acknowledgements

All authors proved substantial input into the conceptualization, drafting and editing of this report. Each has given approval for the publication of the article.

Funding: none

REFERENCES

1. Doran H, Palazzo F. Ambulatory thyroid surgery: Do the risks overcome the benefits? *Presse Med.* 2014; 43: 291-296.
2. Garberoglio R, Aliberti C, Appetecchia ML et al. Radiofrequency ablation for thyroid nodules: which indications? The first Italian opinion statement. *J Ultrasound* 2015;18:423-430.
3. Cibas ES, Ali SZ. The Bethesda System for reporting Thyroid Cytopathology. *Am J Clin Pathol* 2009;132:658-665
4. Kim Ji-hoon, Baek JH, Lim HK et al. Thyroid Radiofrequency Ablation Guideline: Korean Society of Thyroid Radiology. *Korean J Radiol* 2017;19(4), 2018.
5. Haugen BR, Alexander EK, Bible KC et al. American Thyroid Association Management Guidelines for Adult Patients with Thyroid Nodules and Different Thyroid Cancer. *THYROID* 2016, 26(1); 1-133.
6. Park HS, Beak JH, Park AW et al. Thyroid Radiofrequency Ablation: Updates on Innovative Devices and Techniques. *Korean J Radiol* 2017; 18(4): 615-623.
7. Oddo S, Balestra M, Vera L, Guisti M. Benign Thyroid nodule unresponsive to Radiofrequency ablation treated with laser ablation: a case report. *Journal of Medical Case Reports* 2018; 12:127.
8. Mauri G, Cova L, Monaco C et al. Benign thyroid nodules treatment by percutaneous laser ablation and Radiofrequency ablation. *Int J Hyperth.* 2017;33:295-9.
9. Cesareo R, Pasqualini V, Simeoni C et al. Prospective study of effectiveness of ultrasound-guided radiofrequency ablation versus control group in patients affected by benign thyroid nodules. *J Clin Endocrinol Matab.* 2015;100:460-6.
10. Gharib H, Papini E, Paschke R et al. Medical guidelines for clinical practice for the diagnosis and management of thyroid nodules: executive summary of recommendations. *J Endocrinol Investig.* 2010;33:287-91.
11. Ahn HS, Kim SJ, Park SH. Radiofrequency ablation of benign thyroid nodule evaluation of the treatment efficacy using ultrasonography. *Ultrasonography.* 2016;35:244-52.

Received: May, 2019 – Accepted: June, 2019