

Research Note

First record of *Cathaemasia hians* (Trematoda: Cathaemasiidae) in a new bird host, the Eastern Imperial Eagle (*Aquila heliaca*)

L. JUHÁSOVÁ¹, A. KÖNIGOVÁ¹, L. MOLNÁR², P. MAJOR², I. KRÁLOVÁ-HROMADOVÁ¹, E. ČISOVSKÁ BAZSALOVICSOVÁ^{1,*}

¹Institute of Parasitology, Slovak Academy of Sciences, Hlinkova 3, 040 01 Košice, Slovakia, ORCID: L.J. – 0000-0002-0067-6778, A.K. – 0000-0002-0479-3445, I.K.-H. – 0000-0003-0523-7093, E.Č.B. – 0000-0003-4308-8594; ²Clinic for Birds and Exotic Animals, University of Veterinary Medicine and Pharmacy, Komenského 73, 041 81 Košice, Slovakia, L.M. – 0000-0003-1107-4219

Article info

Received August 16, 2023
Accepted October 20, 2023

Summary

An injured young individual of the Eastern Imperial Eagle (*Aquila heliaca*; Accipitridae) from the Protected Bird Area „Medzibodrožie” in the south-eastern Slovakia was subjected to the complete clinical examination at the Clinic for Birds and Exotic Animals of the University of Veterinary Medicine and Pharmacy. Adult trematodes were isolated from the pharynx of the eagle after oesophagoscopy. The morphological and molecular identification of the flukes confirmed a trematode *Cathaemasia hians* (Cathaemasiidae), the obligate parasite of black storks (*Ciconia nigra*) and white storks (*Ciconia ciconia*). This finding represents the first documented case of *C. hians* in new bird host species and indicates broader spectrum of definitive hosts of the fluke.

Keywords: eagle, parasites, flatworm, molecular identification, *IsrDNA*

Introduction

The Eastern Imperial Eagle (EIE), *Aquila heliaca* Savigny, 1809 (Accipitridae) is a large-sized territorial raptor classified as vulnerable species in the International Union for Conservation of Nature's Red list of Threatened Species (BirdLife International, 2023a). While the global population of the EIE has been declining (Collar *et al.*, 1994; BirdLife International, 2023b), the population size of *A. heliaca* in Europe is estimated around 1800-2200 pairs, reflecting a significant increase compared to previous estimations (Demerdzhiev *et al.*, 2011).

Distribution area of breeding EIE extends along the forest-steppe zone in East-Central Europe, including the Carpathian Basin and Balkan Peninsula, and covers a large part of Eastern Asia up to the Baikal Lake (del Hoyo *et al.*, 1995; Vili *et al.*, 2009). Partially isolated eagle's population is formed in the Carpathian Basin in the territories of northern Serbia, Hungary, Ukraine and Slovakia, and their range extends westward into the Czech Republic and Austria.

Suitable biotopes for nesting pairs of the EIE are localized also in south-western and south-eastern Slovakia (Danko & Chavko, 1996). The EIE is one of the rarest and endangered raptors, which has to be regularly monitored and strictly protected under the local legislations.

The main factors that have a negative impact on the eagle's population are habitat alterations (e.g. increase of intensive farming and forestry, habitat loss and degradation), adult mortality through raptor persecution (e.g. illegal killing, shooting, trapping, and poisoning of birds of prey), and individual mortality along migration routes caused by collisions with electric power lines (BirdLife International, 2023b; Chavko *et al.*, 2014).

Parasitic infections may also influence the health status of the eagles as they cause decreased vitality, weight loss, or immunosuppression (Samour, 2005). The EIE is host of a broad spectrum of parasites, including ectoparasites such as ticks, mites and flies (Fend'a & Lengyel, 2007; Araghi *et al.*, 2015), flukes *Metorchis bilis* (Sitko *et al.*, 2016), *Conodiplostomum spathula* and *Strigea fal-*

* – corresponding author

conis, tapeworms *Cladotaenia spasski*, nematodes *Synhimantus laticeps*, *Porrocaecum angusticolle* and *Baruscapillaria falconis* (Komorová *et al.*, 2017), and protists *Trichomonas gallinae*, *Leucocytzoon toddi* and *Haemoproteus* sp. (Leppert *et al.*, 2004; Demerdzhiev *et al.*, 2023). Thus, a complete clinical and parasitological examination of injured eagles is important in order to determine their overall health status. Parasites can also be detected during the dissection of dead eagles.

In the present paper, flukes isolated from the pharynx of an injured EIE from the south-western Slovakia were subjected to the morphological and molecular identification. The current findings were discussed in a parallel with up-to-date knowledge on the host specificity of flukes determined.

Material and Methods

An Eastern Imperial Eagle male of approximately 1-year-old, was found unable to fly with a broken wing due to a collision with an electric power line in the cadastre of the municipality of Leles in the Latorica Protected Landscape Area in the south-eastern Slovakia in August 2022 (Fig. 1). This territory belongs to the Protected Bird Area called „Medzibodrožie“. The bird was hospitalized, examined and treated in the Clinic for Birds and Exotic Animals at the University of Veterinary Medicine and Pharmacy in Košice, Slovakia. Clinical examination of the eagle's beak cavity revealed photophobic parasites upon entering trachea in the pharynx area. Oesophagoscopy using the endoscope Karl Storz Tele Pack Vet X LED RP 100 and a rigid endoscope with a diameter of 2.7 mm and 30° was thus performed. Standard sedation with Isoflurane by inhalation (Piramal Healthcare Voorschoten, Netherland) and basic fluid therapy (Duphalyte + Physiological saline 80 ml/kg) was provided. The mucosa of the oesophagus showed no visible macroscopic changes, with a normal condition and no bleeding. The endoparasites were localized in the upper half of the oesophagus at the transition from the beak cavity to the oesophagus. Three trematodes were removed from the oesophagus; one individual was morphologically identified according to the taxonomic key of Kostadinova (2005) and two specimens were fixed in 70 % ethanol for molecular identification.

Genomic DNA was isolated from 20 mg of the parasites tissue using the QIAamp® DNA Kit (QIAGEN, Hilden, Germany) following the manufacturer's instructions, diluted in deionized water and stored at -20 °C. The molecular genotyping was based on the partial sequences of the large subunit of the ribosomal RNA gene (*lsrDNA*) using universal primer pairs originally described by Olson *et al.* (2003). For PCR amplification, the forward primer LSU-5 (5'-TAGGTCGACCCGCTGAAYTTAAGCA-3') and the reverse primer 1500R (5'-GCTATCCTGAGGGAACTTCG-3'), were used. The PCR amplifications were run as follows: 5 min at 94 °C as an initial step; then 30 cycles of 1 min at 94 °C, 1 min at 54 °C, and 2 min at 72 °C. The final step was 10 min at 72 °C. The PCR products were loaded on the 1.5 % agarose gel and purified using exonuclease I

and shrimp alkaline phosphatase (Werle *et al.*, 1994).

Sequencing was performed using automatic genetic analyser Applied Biosystems 3130xl (Applied Biosystems, Foster City, California, USA) and BigDye Terminator v3.1 Cycle sequencing kit (Applied Biosystems). Sequencing was performed from both directions using PCR primers and three internal primers: 300F (5'-CAAGTACCGTGAGGGAAAGTTG-3'), 400R (5'-GCAGCTTGACTACACCCG-3'), and (5'-CCGTCTTGAAACACGGACCAAG-3') (Olson *et al.*, 2003). Contiguous sequences were assembled and inspected for errors using the Geneious software (version 10.0.5, Biomatters, Auckland, New Zealand). The obtained sequences were deposited in the GenBank, EMBL, and DDBJ databases under the accession numbers OR415298 and OR415299.

Ethical Approval and/or Informed Consent

Not applicable. Examined Eastern Imperial Eagle was hospitalized in wildlife rehabilitation station at the Clinic for Birds and Exotic Animals, University of Veterinary Medicine and Pharmacy, Komen-ského 73, 041 81 Košice, Slovakia. Parasites were removed by veterinarians for diagnosis purposes using standard veterinary procedure.

Results and Discussion

The main morphological criteria for the identification of fluke were size and flattened shape of the body, appearance of cuticle, localization and shape of oral and ventral suckers, and specification of digestive and reproductive systems (Königová *et al.*, 2015). The morphological examination indicated that the fluke isolated from the oesophagus of injured EIE is *Cathaemasia hians* (family Cathaemasiidae). The taxonomy based on morphological markers was supplemented with the molecular genotyping for more reliable species identification.

Sequence analyses of partial *lsrDNA* (1252 bp) revealed identical sequence structure of both analysed specimens with no intraspecific variation. Comparison of the obtained sequences with data deposited in the GenBank database revealed 99.9 % sequence similarity with partial *lsrDNA* of *Cathaemasia hians* (GenBank accession number KT956947) isolated from the ram's horn snail *Planorbis planorbis* from Czech Republic (Tkach *et al.*, 2016).

The life cycle of *C. hians* involves two intermediate and one definitive hosts. Prosobranch and pulmonate snail species of the families Planorbiidae and Lymnaeidae may serve as the first intermediate hosts (Szidat, 1939; Zhytova & Korol, 2012). In Central Europe, larval development of the parasite occurs specifically in great pond snail *Lymnaea stagnalis* and ram's horn snail *Planorbis planorbis* (Grabda-Kazubska *et al.*, 1990; Faltýnková *et al.*, 2008; Zhytova & Korol, 2012), which are commonly found in permanent swamps often visited by storks. Cercariae develop in typical echinostomatid rediae in snails and penetrate the second intermediate hosts, amphibian tadpoles. Infective metacercariae encyst in con-

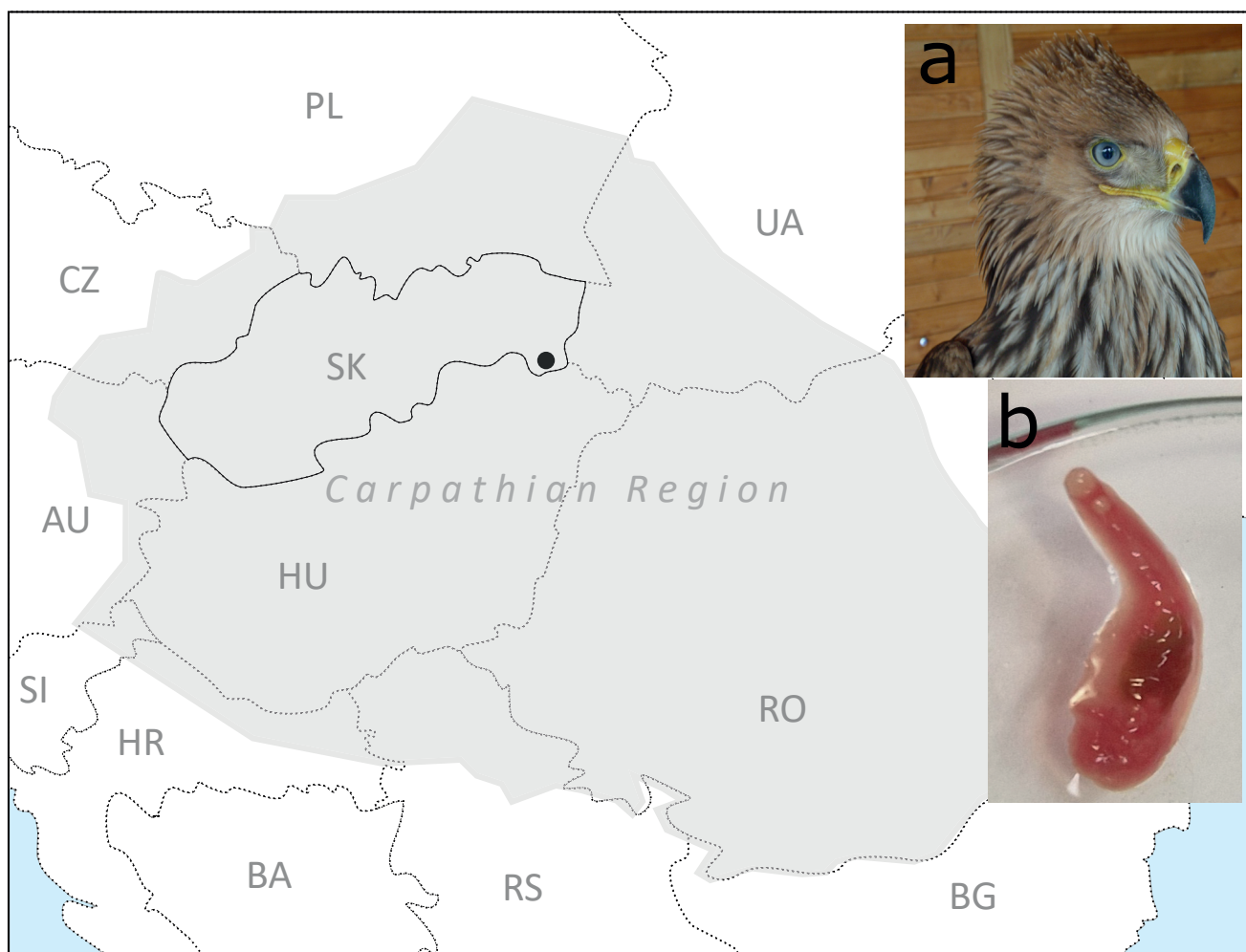


Fig. 1. Schematic presentation of the Carpathian Region and the finding site of *Cathaemasia hians* from an injured Eastern Imperial Eagle (*Aquila heliaca*) in south-eastern Slovakia. a, Eastern Imperial Eagle examined; b, *C. hians* isolated from oesophagus. AU, Austria; BA, Bosnia and Herzegovina; BG, Bulgaria; CZ, Czech Republic; HR, Croatia; HU, Hungary; PL, Poland; RO, Romania; RS, Serbia; SI, Slovenia; SK, Slovakia; UA, Ukraine.

nective tissues in and around the eyes and nares (Grabda-Kazubska *et al.*, 1990; Kostadinova, 2005). The European fire-bellied toad (*Bombina orientalis*), the marsh frog (*Pelophylax ridibundus*), the edible frog (*Pelophylax esculentus*), and amphibians of the family Ranidae serve as the second intermediate hosts of *C. hians* (Volgar-Pastukhova, 1959; Grabda-Kazubska & Lewin, 1989). Birds, definitive hosts of *C. hians*, become infected either by consuming infected frogs or through the passive transfer of highly motile trematodes from the oesophagus of adults to nestlings during feeding (Merino *et al.*, 2001). This obligate trematode species is well-known for infecting birds of the family Ciconiidae (e.g. Merino *et al.*, 2001; Liptovszky *et al.*, 2012; Ramilo *et al.*, 2021). Black storks *Ciconia nigra* and white storks *C. ciconia* were the only confirmed bird species infected with *C. hians* and infections of other species have not been reported until now. Black storks are more susceptible to infection with *C. hians* compared to white storks due to their distinct feeding habits. White storks predominantly

feed on arthropods and earthworms found in dry pastures or in rubbish dumps (Alonso *et al.*, 1991), while black storks feed on frogs or other amphibians, fishes, salamanders and molluscs from swamps and slow flowing waters (Merino *et al.*, 2001; Liptovszky *et al.*, 2012).

Infections of *C. hians* in storks were reported from Hungary (Liptovszky *et al.*, 2012), Spain (Merino *et al.*, 2001), Portugal (Ramilo *et al.*, 2021), Germany (Schuster *et al.*, 2002) and Czech Republic (Sitko & Heneberg, 2015). In Slovakia, the juvenile stages of *C. hians* were found in an oesophagus and cuticle layer of ventriculus of six black storks and 20 white storks (Macko, 1960). The intensity of infection was 4 – 42 and 1 – 86 trematodes in black storks and white storks, respectively. More than 50 years later, a morphological description of *C. hians* isolated from an injured adult black stork in eastern Slovakia was provided along with a detail histopathology of the upper part of the bird's digestive system (Königová *et al.*, 2015).

The *C. hians* infection in the EIE can be explained by the food strategy of this bird of prey. The largest proportion of the diet of the EIE includes mammals, e.g. sousliks (*Spermophilus* sp.), leporids (Leporidae), and hedgehogs (*Erinaceus* sp.), followed by birds (e.g. Corvidae, Laridae, or Ciconiidae) and reptiles (e.g. *Squamata* sp., Testudinidae) (Demerdzhiev *et al.*, 2022). The smaller proportion of the EIE diet is made up of insects, fishes, and also amphibians. The consumption of amphibians infected with metacercariae of *C. hians* represents the potential risk of infection of EIE with this fluke species.

The currently reported *C. hians* infection in the EIE represents the first record of this fluke in new bird host indicating broader host spectrum of *C. hians* than so far documented. We can only hypothesize if the infection of *C. hians* in eagles was previously not detected due to rather rare opportunity for parasitologists and veterinary doctors to perform complete parasitological examination of eagles, or if the infection was previously overlooked during examination or biopsy of EIE. The present data indicate that the inspection of beak cavity and oesophagus of EIE, but also of other birds which have amphibians in their diet, is highly important for more accurate knowledge on the host spectrum of *C. hians*. If the EIE is specific or a dead-end host is unclear yet, and it should be the subject of further investigation.

Conflict of Interest

Authors state no conflict of interest.

Acknowledgement

The work was financially supported by the Slovak Grant Agency VEGA no. 2/0027/21, VEGA no. 1/0308/22, and KEGA 004 UVLF-4/2022.

References

- ALONSO, J.C., ALONSO, J.A., CARRASCAL, L.M. (1991): Habitat selection by foraging White Storks, *Ciconia ciconia*, during the breeding season. *Can J Zoology*, 69: 1957 – 1962. DOI: 10.1139/z91-270
- ARAGHI, M.P., ESKANDARI, F., GILASIAN, E. (2015): Avian wound myiasis caused by *Calliphora vicina* Robineau – Desvoidy (Diptera: Calliphoridae) in an immature migrating Eastern Imperial Eagle (*Aquila heliaca* Savigny) (Aves: Accipitridae) in southwestern Iran. *J Veterinar Sci Technol*, 6: 212. DOI: 10.4172/2157-7579.1000212
- BIRDLIFE INTERNATIONAL (2023a): *Afrom quila heliaca*. In: *IUCN Red List of Threatened Species*. Retrieved June 12, 2023, <https://doi.org/10.2305/IUCN.UK.2019-3.RLTS.T22696048A155464885.en>.
- BIRDLIFE INTERNATIONAL (2023b): In: *Species factsheet: Aquila heliaca*. Retrieved June 14, 2023, from <http://datazone.birdlife.org/species/factsheet/eastern-imperial-eagle-aquila-heliaca>.
- CHAVKO, J., DEUTSCHOVÁ, L., DANKO, Š., MIHÓK, J., LANDSFELD, B., PAVELKA, J., ŠNÍRER, L., HARVANCÍK, S., DUBRAVSKÝ, A., PREŠINSKÝ, L., GALAŠ, R. (2014): Status of the Eastern Imperial Eagle population in Slovakia between 1977 and 2013. *Slovak Rapt J*, 8(1): 9 – 15. DOI: 10.2478/srj-2014-0005
- COLLAR, N.J., CROSBY, M.J., STATTERSFIELD, A.J. (1994): *Birds to watch 2: the world list of threatened birds*. BirdLife Conservation Series No. 4., BirdLife International, Cambridge, UK
- DANKO, Š., CHAVKO, J. (1996): Breeding of the Imperial Eagle *Aquila heliaca* in Slovakia. In: MEYBURG, B.U., CHANCELLOR, R.D. (Eds) *Eagle studies*. London & Paris: World Working Group on Birds of Prey Berlin, pp. 415 – 423
- DEMERDZHEV, D.A., HORVÁTH, M., KOVÁCS, A., STOYCHEV, S., KARYAKIN, I. (2011): Status and population trend of the Eastern Imperial Eagle (*Aquila heliaca*) in Europe in the period 2000 – 2010. *Acta Zool Bulg*, Suppl. 3: 5 – 14
- DEMERDZHEV, D.A., ANGELOV, I., DOBREV, D. (2022): Foraging patterns of non-territorial Eastern Imperial Eagle (*Aquila heliaca*): A case of successful adaptation. *Diversity*, 14(12): 1060. DOI: 10.3390/d14121060
- DEMERDZHEV, D.A., DOBREV, D.D., BOEV, Z.N. (2023): Grassland alterations do not affect breeding success, but can explain dietary shifts of a generalist raptor species. *Diversity*, 15(3): 422. DOI: 10.3390/d15030422
- DEL HOYO, J., ELLIOT, A., SARGATAL, J. (1995): *Handbook of the birds of the World*, Vol. 2. New World Vultures to Guinea-fowl. Barcelona, Spain, Lynx Edicions, 638 pp.
- FALTÝNKOVÁ, A., NAŠINCOVÁ, V., KABLÁSKOVÁ, L. (2008): Larval trematodes (Digenea) of planorbid snails (Gastropoda: Pulmonata) in central Europe: A survey of species and key to their identification. *Syst Parasitol*, 69: 155 – 178. DOI: 10.1007/s11230-007-9127-1
- FENĎA, P., LENGYEL, J. (2007): Mites (Acarina, Mesostigmata) in nests of the white-tailed sea eagle *Haliaeetus albicilla* (L.) in Slovakia. *Entomofauna Carpath*, 19: 48 – 50
- GRABDA-KAZUBSKA, B., LEWIN, J. (1989): The helminth fauna of *Bambina bombina* (L.) and *B. variegata* (L.) in Poland. *Acta Parasitol Pol*, 34(3): 273 – 279
- GRABDA-KAZUBSKA, B., BAYSSADE-DUFOUR, C., KISELIENE, V. (1990): Chaemotaxy and excretory system of *Echinocercaria choanophila* U. Szidat, 1936, a larval form of *Cathaemasia hians* (Rud., 1809) (Trematoda, Cathemasiidae). *Acta Parasitol Pol*, 35(2): 97 – 105
- KOMOROVÁ, P., SITKO, J., ŠPAKULOVÁ, M., HURNÍKOVÁ, Z., SALAMATIN, R., CHOVANCOVÁ, G. (2017): New data on helminth fauna of birds of prey (Falconiformes, Accipitriformes, Strigiformes) in the Slovak Republic. *Helminthologia*, 54(4): 314 – 321. DOI: 10.1515/helm-2017-0038
- KOSTADINOV, A. (2005): Family Cathemasiidae Fuhrmann, 1928. In: JONES, A., BRAY, R.A., GIBSON, D.I. (Eds) *Keys to the Trematoda*. Volume 2. London, UK: CABI Publishing and The Natural History Museum, UK, pp 69 – 73
- KÖNIGOVÁ, A., HRČKOVÁ, G., MOLNÁR, L., MAJOR, P., VÁRADY, M. (2015): *Cathaemasia hians* in Black stork in Slovakia: morphological and histopathological study. *Helminthologia*, 52(4): 316 – 322. DOI: 10.1515/helmin-2015-0050

- LEPPERT, L.L., LAYMAN, S., BRAGIN, E.A., KATZNER, T. (2004): Survey for hemoparasites in Imperial Eagles (*Aquila heliaca*), Steppe Eagles (*Aquila nipalensis*), and White-tailed Sea Eagles (*Haliaeetus albicilla*) from Kazakhstan. *J Wildl Dis*, 40(2): 316 – 319. DOI: 10.7589/0090-3558-40.2.316
- LIPTOVSKY, M., MAJOROS, G., PERGE, E. (2012): *Cathaemasia hians* in a Black Stork (*Ciconia nigra*) in Hungary. *J Wildl Dis*, 48(3): 809 – 811. DOI: 10.7589/0090-3558-48.3.809
- MACKO, J.K. (1960): On the fauna of plathelminthes of Black stork – *Ciconia nigra*. L. *Biologia*, 7: 549 – 552
- MERINO, S., MARTINEZ, J., LANZAROT, P., CANO, L.S., FERNANDEZ-GARCIA, M., RODRIGUEZ-CAABEIRO, F. (2001): *Cathaemasia hians* (Trematoda: Cathaemasiidae) infecting black stork nestlings (*Ciconia nigra*) from central Spain. *Avian Pathol*, 30(5): 559 – 561. DOI: 10.1080/03079450120078761
- OLSON, P.D., CRIBB, T.H., TKACH, V.V., BRAY, R.A., LITTLEWOOD, D.T.J. (2003): Phylogeny and classification of the Digenea (Platyhelminthes: Trematoda). *Int J Parasitol*, 33(7): 733 – 755. DOI: 10.1016/S0020-7519(03)00049-3
- RAMILO, D.W., CAETANO, I., BRAZIO, E., MIRA, M., ANTUNES, L., DA FONSECA, I.P., CARDOSO, L. (2021): Presence of one ecto- and two endoparasite species of the black stork (*Ciconia nigra*) in Portugal. *BMC Vet Res*, 17(1): 21. DOI: 10.1186/s12917-020-02724-6
- SAMOUR, J. (2005): Management of Raptors. In: HARRISON, G.H., LIGHTFOOT, T. (Author), *Clinical Avian Medicine*, Volumes 1 & 2, Chapter 40, Spix Publishing, Florida, USA
- SCHUSTER, R., SCHAFFER, T., SHIMALOV, V. (2002): Die Helminthenfauna einheimischer Weisstörche (*Ciconia ciconia*) [The helminth fauna of native white storks (*Ciconia ciconia*)]. *Berl Munch Tierarztl Wochenschr*, 115: 435 – 439 (In German)
- SITKO, J., HENEBERG, P. (2015): Composition, structure and pattern of helminth assemblages associated with central European storks (Ciconiidae). *Parasitol Int*, 64(2): 130 – 134. DOI: 10.1016/j.parint.2014.11.004
- SITKO, J., BIZOS, J., SHERRARD-SMITH, E., STANTON, D.W.G., KOMOROVÁ, P., HENEBERG, P. (2016): Integrative taxonomy of European parasitic flatworms of the genus *Metorchis* Looss, 1899 (Trematoda: Opisthorchiidae). *Parasitol Int*, 65(3): 258 – 267. DOI: 10.1016/j.parint.2016.01.011
- SZIDAT, L. (1939): Beiträge zum Aufbau eines natürlichen Systems der Trematoden. I. Die Entwicklung von *Echinocercaria choanophila* u. Szidat zu *Cathaemasia hians* und die Ableitung der Fasciolidae von den Echinostomidae. *Z Parasitenkd*, 11: 239 – 283
- TKACH, V.V., KUDLAI, O., KOSTADINOVA, A. (2016): Molecular phylogeny and systematics of the Echinostomatoidea Looss, 1899 (Platyhelminthes: Digenea). *Int J Parasitol*, 46(3): 171 – 185. DOI: 10.1016/j.ijpara.2015.11.001
- VILI, N., CHAVKO, J., SZABÓ, K., KOVÁCS, S., HORNUNG, E., KALMÁR, L., HORVÁTH, M. (2009): Genetic structure of the Imperial Eagle (*Aquila heliaca*) population in Slovakia. *Slovak Rapt J*, 3: 21 – 28. DOI: 10.2478/v10262-012-0029-z
- VOLGAR-PASTUKHOVA, L.G. (1959): The parasite fauna of Anura of the Danube delta. In: POLYANSKI, Y.I. (Ed) *Ekologicheskaya Parazitologiya*, pp 58 – 95
- WERLE, E., SCHNEIDER, C., RENNER, M., VOLKER, M., FIEHN, W. (1994): Convenient single step, one tube purification of PCR products for direct sequencing. *Nucleic Acids Res*, 22(20): 4354 – 4355. DOI: 10.1093/nar/22.20.4354
- ZHYTOVA, O.P., KOROL, E.M. (2012): *Cathaemasia hians* (Digenea, Cathaemasiidae) from *Planorbis planorbis* (Mollusca, Gastropoda) in Reservoirs of Central Polissya. *Vest Zool*, 46(4): e-42 – e-45. DOI: 10.2478/v10058-012-0029-6